

A WOMAN WITH CHEST PAIN, DYSPNEA, AND A THORACIC MASS



Duke



Briguglio



Bator

Lee M. Duke, M.D., MBA
John Briguglio, M.D.
Susan M. Bator, M.D.

Departments of Pulmonary Medicine,
Radiology, and Pathology
Lancaster General Health/Penn Medicine

HISTORY

A 55-year old woman was seen in the Lancaster General Hospital Emergency Department (ED) with the chief complaint of right-sided pleuritic chest pain, cough, and dyspnea, associated with low grade fevers, poor appetite with weight loss, and drenching sweats. She had been in her usual health until four to six weeks prior to admission when she developed the symptoms of an upper respiratory infection with sinus congestion.

Her relevant history included seasonal allergies and asthma. She also had lived for many years in the Southwestern United States. She had hypothyroidism secondary to autoimmune thyroiditis, and hypertension. She had never smoked, did not drink alcohol, and was not aware of any occupational or avocational exposures to hazardous or toxic materials. Her family history was negative for cardiopulmonary disease.

She had been seen by her primary physician, who had treated her with oral steroids, levofloxacin, and nasal steroids for an exacerbation of her seasonal allergies and asthma, but her symptoms worsened, and she was seen in the ED.

CLINICAL COURSE

Her initial chest X-ray showed an area in the right upper lobe that was interpreted as showing an infiltrate or a mass. She was admitted directly from the ED and was seen in consultation by the pulmonary service. Their differential diagnosis included atypical pneumonia, malignancy, autoimmune disease, or an inflammatory process.

Laboratory studies revealed an elevated ESR, but negative QuantiFERON-Tb® Gold Test, Urinary legionella antigen, ANA, pANCA and cANCA.

CT scan of the chest showed a >5 cm. mass-like density in the right upper lobe with a focus of gas or cavitation. (Fig. 1)

Interventional radiology was consulted for a

transthoracic needle biopsy, which was done four days later with CT guidance. The scan at this time already suggested some improvement in the right-sided mass. (Fig. 2)

The *needle biopsy* revealed benign lung tissue with an inflammatory organizing pneumonia, an abscess, and fibroblastic foci. There were no granulomas, and special stains for AFB and fungi were negative.

Three of the microscopic sections are presented:

Fig. 3 displays the abscess surrounded by acute and chronic inflammatory tissue.

Fig. 4 at higher power identifies bronchial epithelium.

Fig. 5 at higher power shows chronic inflammatory tissue with fibrosis.

A diagnosis of *Bronchiolitis Obliterans Organizing Pneumonia* was made. Intravenous methylprednisolone

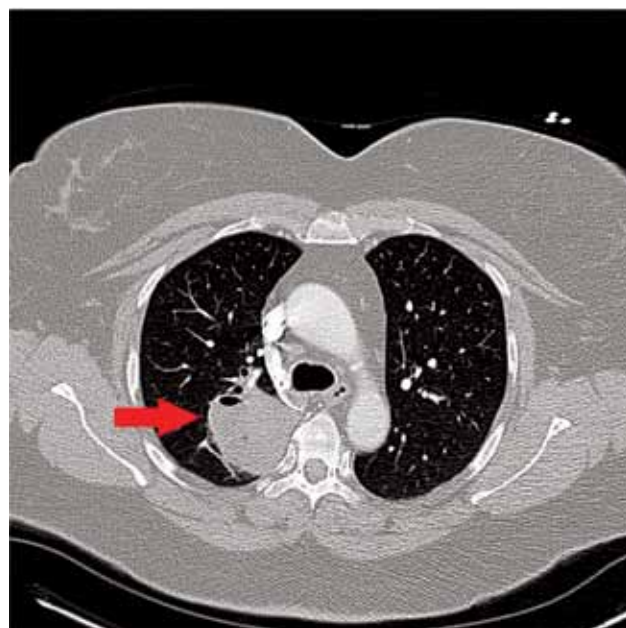


Fig. 1. A CT scan of the chest shows a >5 cm mass-like density in the right upper lobe with a focus of gas or cavitation.

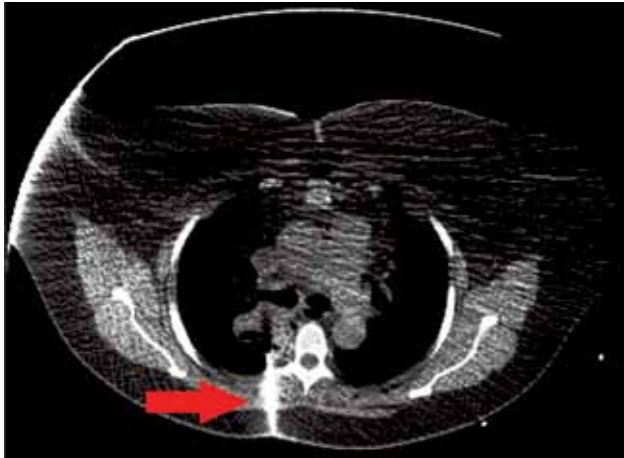


Fig. 2 Percutaneous CT-guided core biopsy of the right upper lobe mass with an 18 G needle was performed. The needle can be seen as a bright object inserted posteriorly next to the spine. Though this slice is not at the same level as the section in Fig. 1, comparable sections show that the mass is already improving.

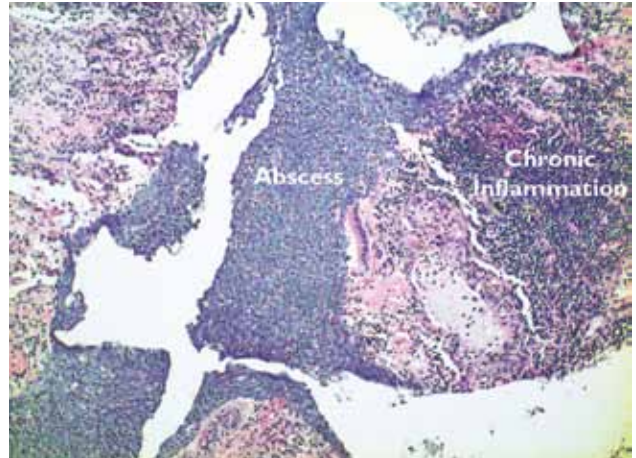


Fig. 3. A histologic section from the needle biopsy specimen that displays the abscess surrounded by acute and chronic inflammatory tissue.

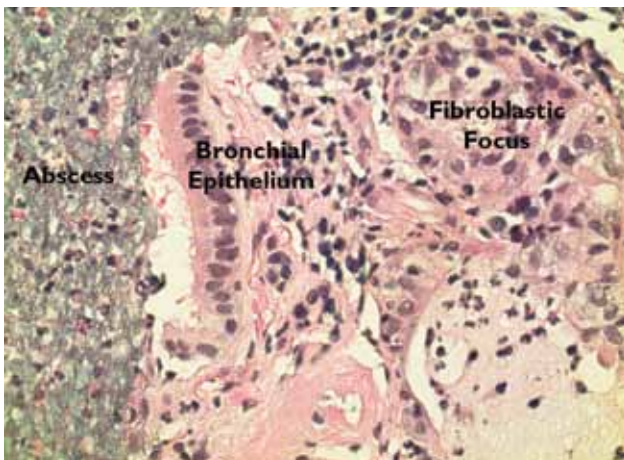


Fig. 4. A higher power section that identifies bronchial epithelium more clearly.

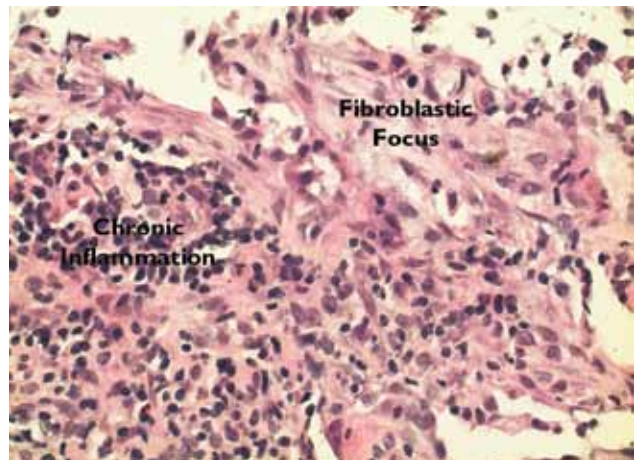


Fig. 5. A higher power view that shows chronic inflammatory tissue with fibrosis.

had been started, and the patient quickly improved with resolution of her temperature and sweats. With this favorable response and the biopsy results, the patient was discharged with outpatient follow-up in the pulmonary office.

A CT scan of the chest five weeks after presentation showed that the right upper lobe mass had decreased in size to 4 cm. It was thin-walled and primarily gas-filled, but with some residual fluid. (Fig. 6)

Steroids were tapered over a three-month period. A CT scan of the chest 10 weeks after presentation showed a nearly resolved right upper lobe density with a thin-walled, gas-filled scar remaining. (Fig. 7) Scattered small nodules were seen bilaterally including a 1.2 cm

density in the right lower lobe. PET scanning did not show uptake in these nodules, consistent with scarring. (Fig. 8) Continued CT follow-up is planned.

DISCUSSION

Cryptogenic Organizing Pneumonia, also known as *Bronchiolitis Obliterans Organizing Pneumonia*, is a rare condition estimated to affect less than 10 cases per 100,000 admissions. In most cases the cause is unknown, but the condition has been associated with connective tissue disease, drugs such as chemotherapy and amiodarone, and malignancy.

Both men and women in the fifth and sixth decades are about equally affected. They often present with symptoms of cough, dyspnea, fever, and chest discomfort

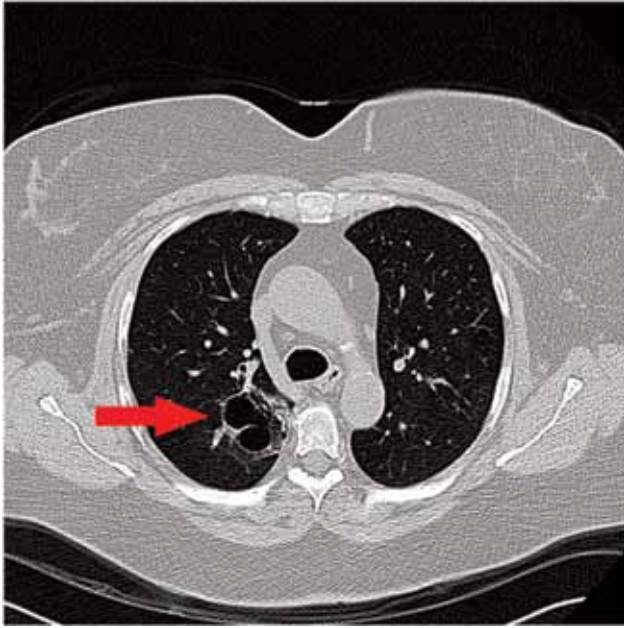


Fig. 6. A CT scan of the chest five weeks after presentation shows that the right upper lobe mass has decreased in size to 4 cm. It is thin-walled and primarily gas-filled, but with some residual fluid.

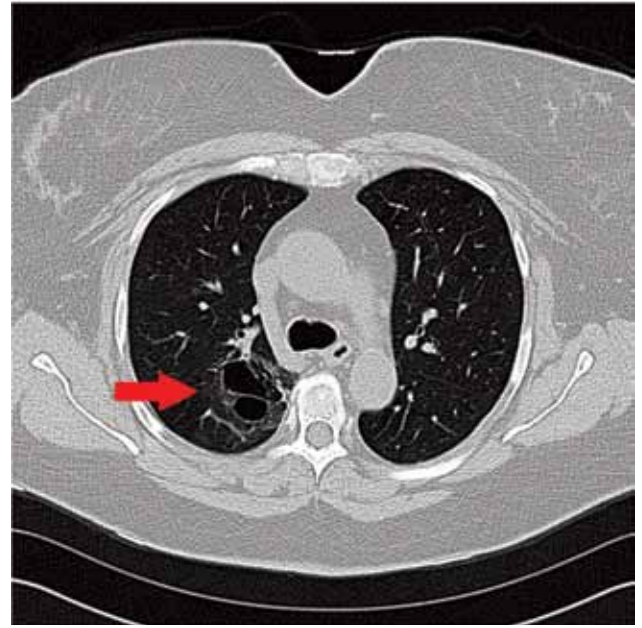


Fig. 7. CT scan of the chest 10 weeks after presentation shows a nearly resolved, mass-like, right upper lobe density with a thin-walled, gas-filled scar. The complete study shows scattered nodules (see text).

several weeks after an upper respiratory infection.

The pathologic response is triggered by alveolar injury and protein leakage, with amplification of the inflammatory response. Proliferation of excessive granulation tissue plugs the distal bronchioles and alveolar ducts, leading to ventilation-perfusion mismatch and hypoxemia.

The treatment of choice is systemic steroids, e.g. methylprednisolone, 1 mg/kg/day, which yields a high response rate. The condition can relapse after tapering the steroids, and other immunosuppressive drugs have been used when this occurs.

Lee M. Duke, M.D.
Senior Vice President & Chief Physician Executive
Lancaster General Health/Penn Medicine
Pulmonary Associates of Lancaster Ltd.
717-544-4695; lmduke@lghealth.org

John Briguglio, M.D.
Chairman, Department of Radiology
Lancaster General Health/Penn Medicine
Lancaster Radiology Associates Ltd.
717-299-4173; JOBriguglio@lghealth.org

Susan M. Bator, M.D.
Department of Pathology
Lancaster General Health/Penn Medicine

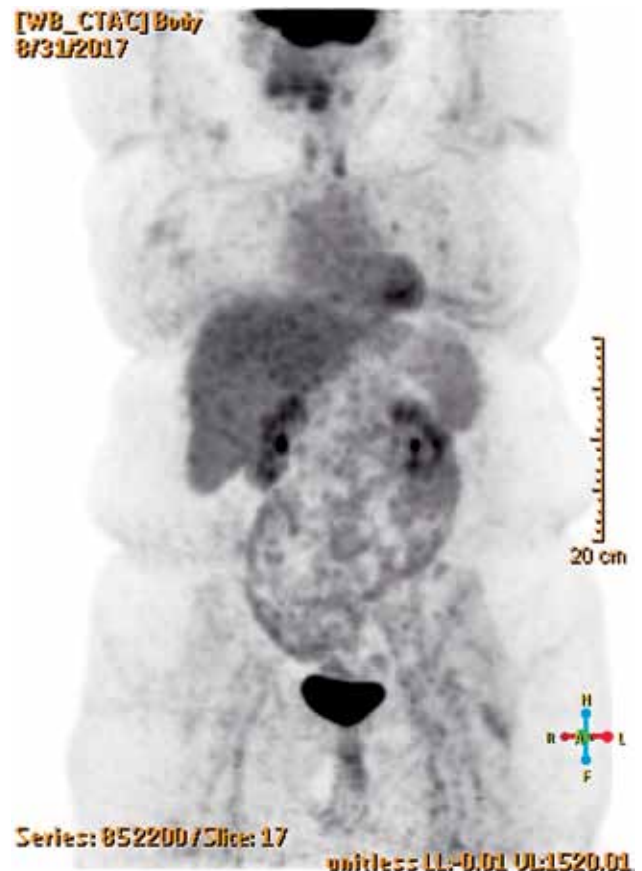

Fig. 8. PET-CT scan four months after presentation shows no abnormal FDG activity in the lungs or elsewhere.