



BREAST CANCER SURGERY AND ONCOPLASTIC TECHNIQUES

Aaron D. Bleznak, MD, MBA, FACS

Medical Director Breast Program, Ann B. Barshinger Cancer Institute
Penn Medicine Lancaster General Health

INTRODUCTION

For more than a century after the standardization of the radical mastectomy procedure by William Stewart Halsted at Johns Hopkins in the late 19th century, the mainstay of breast cancer treatment has been surgical resection. Removal of the primary breast cancer is curative for those women whose malignancy has not metastasized to distant sites, and in the current era of mammographic screening, that is the fortunate status of most women when their breast cancer is first diagnosed.

Our understanding of the route of breast cancer metastasis has evolved since Halsted's time. His theory of initial spread via lymphatic channels, which eventually empty into the vascular system, has evolved into our current appreciation that primary spread is hematogenous. This understanding has resulted in the employment of systemic therapies for a larger percent of women with early stage breast cancer, but despite these advances, surgical resection of breast cancer continues to be a central component of curative therapy.

TRENDS IN BREAST CANCER SURGERY

In 1985, the results of the National Surgical Adjuvant Breast Program (NSABP B-06) study, which

compared total mastectomy to lumpectomy (breast conserving surgery or BCS) with or without radiation therapy, demonstrated that the extent of surgery does not impact cure rates^{1,2} (Fig. 1). Other randomized trials in the United States and internationally, with as much as 35 years of follow-up, have confirmed that the extent of resection does not affect disease-specific and overall survival rates.³

Over the ensuing decade after the landmark NSABP B-06 study, these lessons were incorporated into oncologic practice, and we achieved a relatively steady state in rates of breast conservation (Fig. 2, next page). From 2007 to 2016, breast-conserving surgery was used in approximately 60% of women with breast cancer cared for in hospitals accredited by the Commission on Cancer. It is estimated that approximately 20% of women with breast cancer require mastectomy due to absolute contraindications to breast conservation (prior radiation therapy, multicentric breast cancer, extensive radiographic abnormalities, first/second trimester of pregnancy), or relative contraindications (BRCA or other germ line mutation or connective tissue disorder). The "delta" between the 20% who require mastectomy and the 40% who currently receive it is comprised of women who opt for mastectomy for one of several clinical reasons plus those who are advised or choose to have mastectomy, often due to concerns regarding the cosmetic outcome of breast conservation.

At Lancaster General Hospital, the BCS rate for 2015-16 was 53.6%, below the 61-62% figure from the National Cancer Database institutions and significantly below the 63.8% for all Pennsylvania hospitals. For fiscal year 2019, however, our BCS rate has risen to 63.8%. A major factor in this change has been the introduction of oncoplastic breast cancer surgery, the subject of this article.

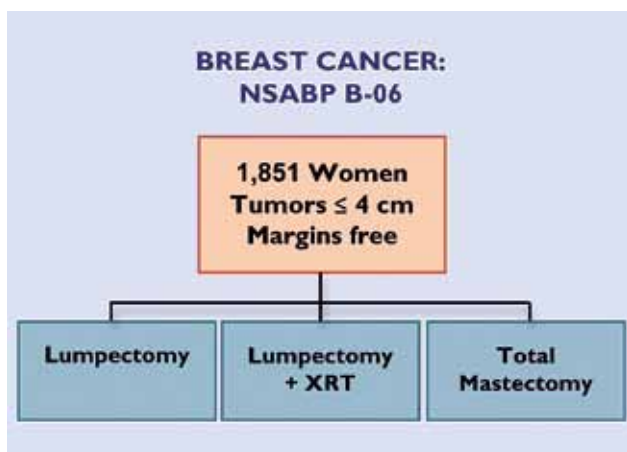


Fig. 1. Schema for NSABP B-06.

WHAT IS ONCOPLASTIC BREAST SURGERY?

When the NSABP B-06 study was released, there

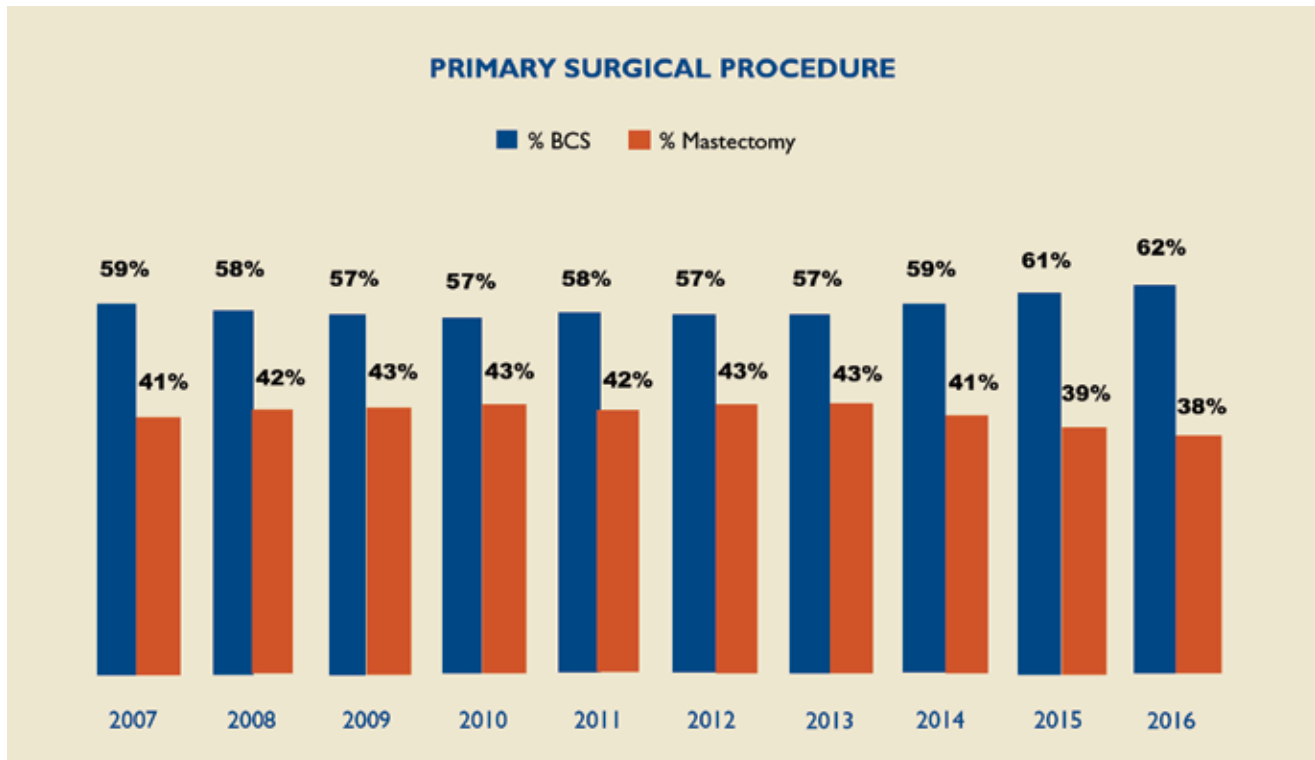


Fig. 2. Primary surgical procedure by year for the ~1,500 CoC-accredited hospitals in the National Cancer Database.

were limited suggestions as to placement and closure of surgical incisions for lumpectomies. The conventional approach was to use curvilinear incisions placed within Langer's Lines (Fig. 3a, page 103) and to close the subcutaneous tissue, dermis, and skin only, leaving a cavity that usually filled initially with fluid (a seroma). These techniques worked well for small cancers (T1) and moderate-sized (T2) cancers in women with average breast size and for larger cancers in women with larger breasts. However, this approach left a considerable number of women without the option of breast conservation if they had larger cancers or lesser breast volume. In addition, over time it was increasingly recognized that post-radiation fibrosis, particularly in women with larger breasts and/or reabsorption of the seroma adversely impacted the cosmetic outcome. Many women developed alterations in the contour of the breast, such as skin or nipple retraction or deviation, months or even years after completion of therapy (Fig. 3b, page 103).

Over the past 10-15 years, techniques have been developed that not only mitigate adverse cosmetic results after breast conserving surgery but also increase the number of women who are candidates for it. These efforts began in France, where breast surgeons have extensive training in plastic

and reconstructive surgery, and subsequently developed in the United States with the proliferation of dedicated breast surgeons and the advent of breast surgical oncology fellowships that included rotations in plastic surgery.

These techniques, some detailed below, provide equal weight to the oncologic and cosmetic outcomes of the surgical procedure. They require thorough preoperative assessment of the native appearance of the breasts (degree of symmetry and ptosis), including measurement of key distances (e.g. sternal notch to nipple), and counseling of the patient about the surgical options. These procedures are greatly facilitated by use of intraoperative ultrasound and/or cooperation with radiology to assure that areas of abnormal imaging are included in the resection, as subsequent re-excision procedures are difficult. Finally, select cases require consultation/co-management with a plastic and reconstructive surgeon, such as for reduction mastoplasty in conjunction with partial mastectomy. In all cases, the breast surgeon must first assure that an appropriate and optimal oncologic resection is performed.

ONCOPLASTIC PROCEDURES

This section describes some of the most common

oncoplastic procedures performed by breast oncology surgeons at Penn Medicine Lancaster General Hospital. (This is not a complete listing of possible procedures.)

Local Rotation Flap

This procedure is based on “robbing Peter to pay Paul.” The defect is filled with breast parenchymal tissue or subcutaneous adipose tissue mobilized from a region of the breast which will not manifest the defect (e.g. deeply situated breast tissue adjacent to the pectoralis fascia), or from de-epithelialized tissue adjacent to the lumpectomy cavity (Fig. 4, page 103).

Inframammary Crease Incision

With the use of intraoperative ultrasound, some cancers can be approached from posterior to the breast tissue (i.e. the retro-mammary adipose tissue plane). An incision can be “hidden” in the inframammary crease (Fig. 5a, page 103) and the breast tissue is then mobilized off the pectoralis major muscle (Fig. 5b, page 103), employing ultrasound to guide the excision. If required, deeper breast tissue can be utilized as a rotation flap to fill the superficial, subcutaneous defect as described above.

Mastoplastic Closure

The NSABP recommended against closure of deep defects based upon experience with subsequent skin or nipple retraction. However, with current techniques that often utilize extensive dissection of the breast parenchyma off the underlying pectoralis fascia and away from the subcutaneous tissue, substantial mobilization of breast tissue can allow the edges of the lumpectomy cavity to be approximated without resulting in skin retraction or unintentional nipple displacement. This technique is especially useful when the affected breast is of larger volume than the contralateral unaffected breast, as the mammoplasty often reduces overall breast volume while maintaining the contour of the breast. When some of the skin around the areola is circumferentially excised, this is referred to as a “donut” mastoplastic (Fig. 6, page 104).

Mastopexy Closure

In some cases, there is a greater degree of ptosis of the nipple on the affected breast and this can be corrected with skin excision and resection of the breast tissue including the malignancy. Fig. 7 (page 104) depicts a “batwing” mastopexy (so known because

the excision loosely resembles a bat silhouette). This approach is appropriate for cancers in the upper half of the breast. Fig. 8 (page 104) shows closure after a “hemi-batwing” mastopexy, which is employed more frequently by LGH breast surgeons.

For cancers of the inferior half of the breast, resection of the cancer can also be combined with a mastopexy closure (Fig. 9, page 105).

Reduction Mastoplastic in Conjunction with Lumpectomy

Some oncoplastic procedures are best performed by breast oncology surgeons in conjunction with plastic and reconstructive surgeons. Women diagnosed with breast cancer who also have macromastia, particularly when symptomatic, can be offered bilateral breast reduction surgery in conjunction with an oncologic resection (lumpectomy). This approach may allow for removal of an extensive area of proven or suspected cancer or radiologic abnormality with an excellent cosmetic outcome and often ameliorates the neck and upper back pain that accompanies significant macromastia.

These procedures require collaboration among the breast surgeon, radiologist, and reconstructive surgeon to assure that the area of concern is well-marked and fully excised. A return to the operating room for re-excision because of inadequate margins can be technically difficult, as identification of the original margins of resection is often unreliable. In conventional non-oncologic reduction mammoplasty the nipple is preserved, and this is often true of many cases of lumpectomy with reduction mammoplasty. In some cases, however, the nipple areolar complex must be sacrificed for oncologic reasons.

Oncoplastic Mastectomies

When mastectomy is the best option, patients at LGH are now offered immediate reconstruction, and approximately 50% select this approach. In most cases, either skin-sparing or nipple-sparing techniques are performed in conjunction with implant-based or autologous tissue reconstructions, resulting in improved cosmetic outcomes as compared to total mastectomies.

SUMMARY

Oncoplastic breast surgery techniques require analysis of both the patient’s body habitus and the extent of malignancy, individualized preoperative planning for the best surgical approach, and

collaboration among the breast oncology surgeon, radiologist, and – in some instances – the plastic and reconstructive surgeon. These surgical options increase the number of patients who are candidates for breast conservation, result in a larger percent of patients with resection margins that are negative for cancer, and provide better cosmetic outcomes following breast conservation and radiation therapy.

Eighty percent of women with newly diagnosed breast cancer can now be offered the option of breast-preserving surgery without sacrificing oncologic efficacy. This fortuitous circumstance is due to the availability of surgeons who have experience with these techniques, coupled with the appropriate identification of patients who should receive neoadjuvant systemic therapies, which frequently reduce the volume of cancer to be excised. The more than 10% increase in breast conserving surgery for patients presenting to

Penn Medicine Lancaster General Health in fiscal year 2019 reflects, in part, the availability and employment of these surgical techniques.

It is exciting to consider future directions in the local management of breast cancer. The American College of Surgeons Oncology Group 1071 investigated cryoablation of breast cancer, and the effectiveness of breast MRI scan in identifying those women who had complete eradication of viable malignancy.⁴ The author contributed three patients to this study, all whom had cancers smaller than 15 mm, and all of whom had 100% cancer destruction by this technique. In the entire trial, 66 of 87 evaluable patients (76%) had complete ablation (no residual viable cancer seen pathologically). Although MRI did not reliably predict the outcome of the cryotherapy, this study did demonstrate the feasibility of ablation for carefully selected, small breast cancers.

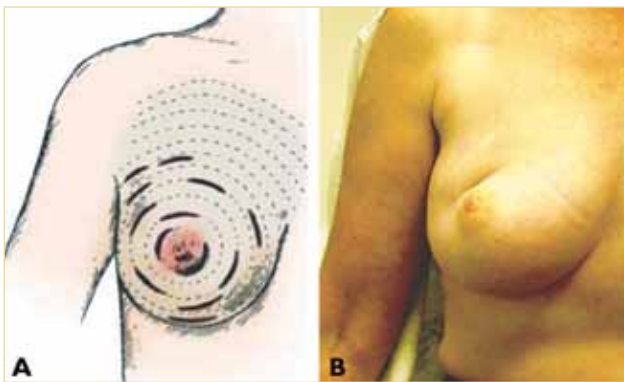


Fig. 3a. Recommended NSABP incisions (N Engl J Med. 1985 Mar 14;312(11):665-73).

Fig. 3b. Example of skin retraction and nipple deviation from a lumpectomy with skin only closure.

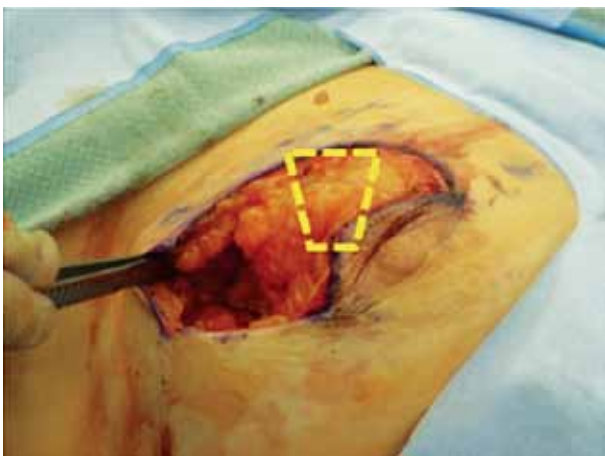

Fig. 4. The de-epithelialized breast tissue above the areola (as indicated) is rotated counterclockwise to fill the defect inferior to the forceps.

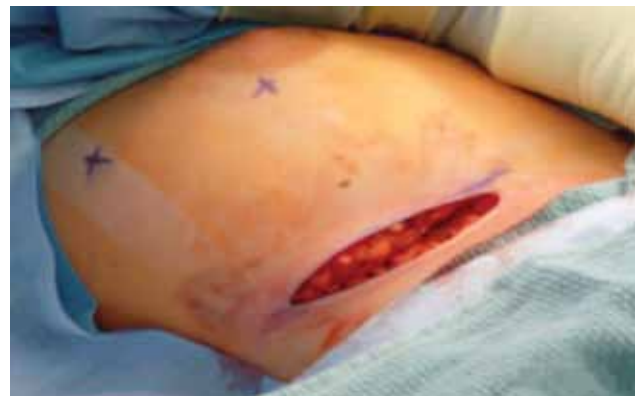

Fig. 5a. Inframammary crease incision with Xs marking the location of the two tumors.

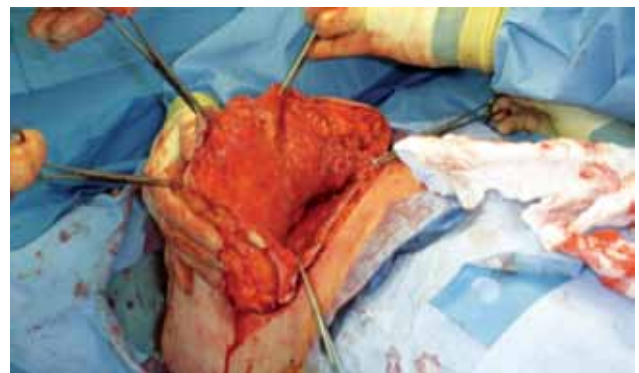

Fig. 5b. This picture demonstrates the extensive mobilization.

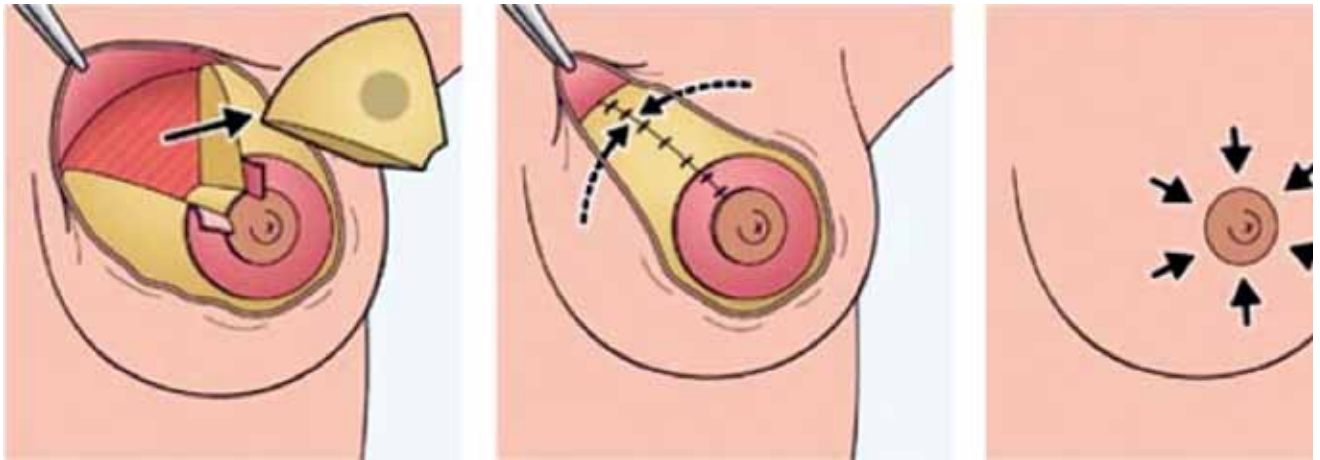


Fig. 6. Mastoplasty closure. (Source: linkgalegroup.com)

Batwing Mastopexy (a common oncoplastic technique)

Breast shape is preserved and scars are hidden under clothing

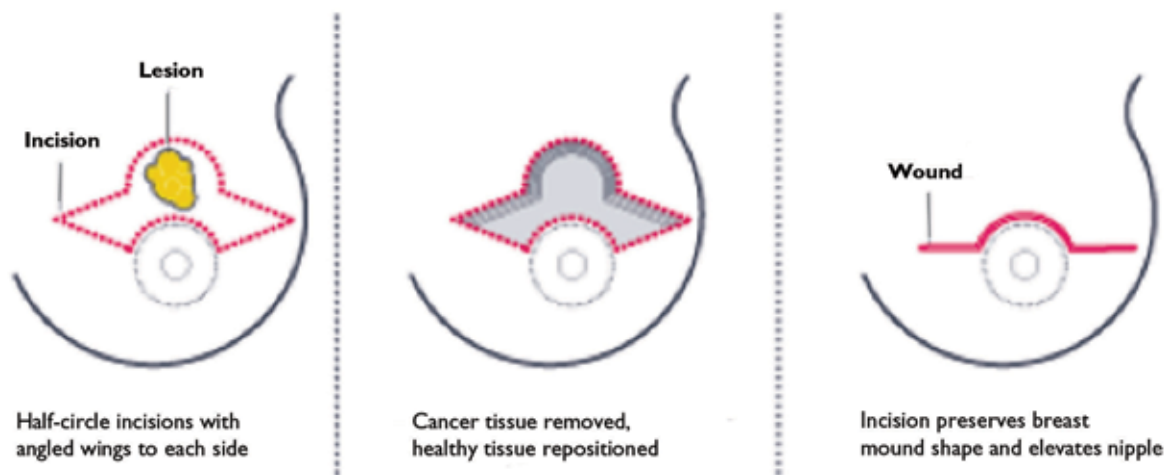
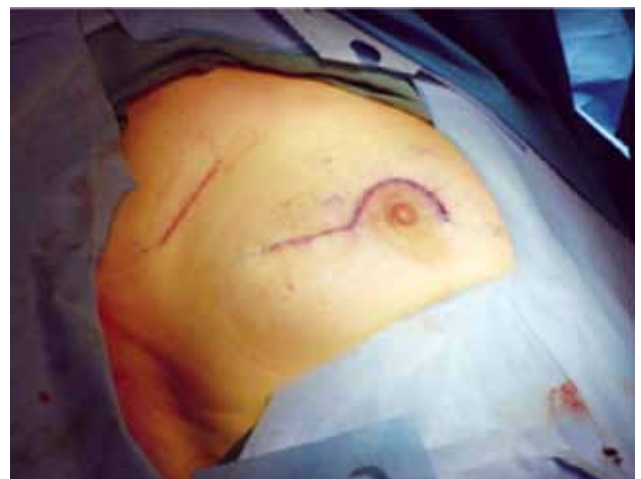

Fig. 7. Batwing resection with mastopexy closure. (Source: *The Lancet*, Dr. Melvin Silverstein).

Fig. 8. Closure after hemi-batwing resection and sentinel node biopsy.



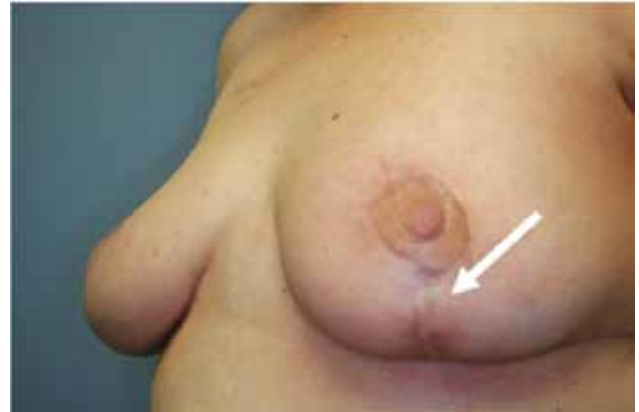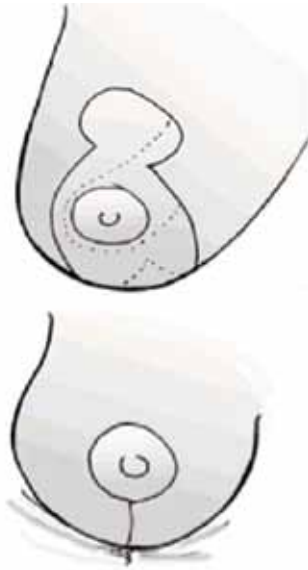


Fig. 9a (left) and 9b (above).
Diagram and image of resection
of inferior pole cancer and
mastopexy closure.

Other studies have evaluated different forms of energy, such as laser or radiofrequency ablation, for destruction of cancer. Still other centers are assessing the adequacy of imaging, including MRI and PET-CT, coupled with multiple percutaneous biopsies, to identify

the subset of patients treated with neoadjuvant systemic therapies who have had complete eradication of their local disease. The ultimate in oncoplastic surgery in the next decade may be ablation of cancer without surgical resection for carefully selected patients.

REFERENCES

1. Fisher B, Bauer M, Margolese R, et al. Five-year results of a randomized clinical trial comparing total mastectomy and segmental mastectomy with or without radiation in the treatment of breast cancer. *N Engl J Med.* 1985; 312(11): 665-673.
2. Fisher B, Jeong J-H, Anderson S et al. Twenty-five year follow-up of a randomized trial comparing radical mastectomy, total mastectomy and total mastectomy followed by irradiation. *N Engl J Med.* 2002;397:567-575.
3. Veronesi U, Cascinelli N, Del Vecchio M, et al. Comparing radical mastectomy with quadrantectomy, axillary dissection, and radiotherapy in patients with small cancers of the breast. *N Engl J Med.* 2002; 347:1227-1232.
4. Simmons RM, Ballman KV, Cox C, et al. A Phase II trial exploring the success of cryoablation therapy in the treatment of invasive breast carcinoma: Results from ACOSOG (Alliance) Z1072. *Ann Surg Oncol.* 2016;23(8):2438-2445

Aaron D. Bleznak, M.D.
Penn Medicine LG Health Physicians Surgical Group
2104 Harrisburg Pike, Suite 200
Lancaster, PA 17604-3200
717-544-3626
Aaron.Bleznak@pennmedicine.upenn.edu